

CLINICAL IMAGES

Two Cases of Accidentally Swallowed Toothbrush ; A Clue To Bulimia Nervosa

Vijant Singh Chandail, Vinu Jamwal

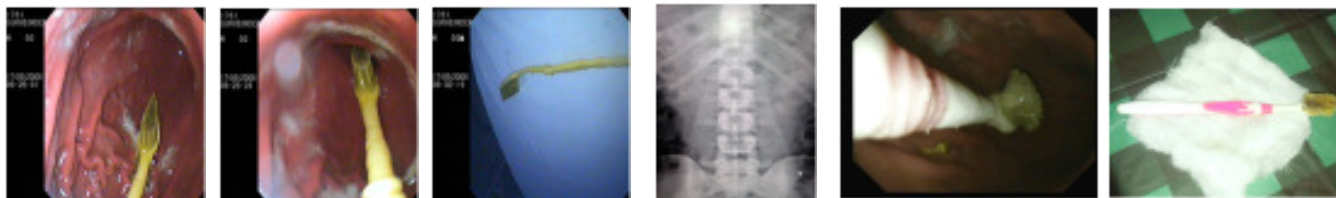


Fig1&2. Endoscopic View of Tooth Brush

Fig 3&4 . Showing Tooth Brush Removed Endoscopically and X Ray Abdomen Showing Tooth Brush

Fig5&6. Showing Tooth Brush Removed Endoscopically in case 2

Bulimia, compulsive binge eating and purging, may affect as many as 20% of adolescent girls and 1 to 2% of men if broader diagnostic criteria are used (1). Swallowing a toothbrush is a rare and uncommon situation and poses a special problem, as it never passes through the gastrointestinal tract spontaneously because of its unique shape and is associated with complications like gastritis, ulcerations and perforation. So early endoscopic removal is advisable to prevent complications and endoscopic removal is associated with minimal morbidity, prompt recovery and discharge.

A thirty six years old male & another thirty one years old male presented to our hospital with history of having swallowed a toothbrush while attempting to induce vomiting the previous day. They complained of mild discomfort in the abdomen following swallowing. The frontal and lateral plain films of the abdomen revealed parallel rows of metallic densities in the left upper quadrant within the stomach (*Fig 4*). Esophagogastroscopy was performed (GIF V70; Olympus, Japan) under conscious sedation with 1.5 mg of injection midazolam. Whole of the adult size tooth brush was lying in the stomach with the handle in the fundus of stomach and the bristle end in the antrum (*Fig 1, 2 & 5,6*). The handle of the toothbrush was caught with a polypectomy snare and the toothbrush was taken out along with the scope (*Fig 3*). There were no postprocedure complications and the patients were allowed orals after 1 hour of the procedure and were discharged after 2 hours. After taking both the patients

into confidence, patients revealed the history of compulsive binge eating and purging, suggestive of bulimia nervosa. The patient were subsequently attended by psychiatrist and are on their followup since then and are doing well. In contrast to the characteristic coupled binge/vomit episodes, ingestion of foreign bodies such as swallowing of toothbrush is a rare event in bulimia nervosa (2). Most of the reported cases have associated neurological or psychiatric disorders in the form of bulimia nervosa, anorexia nervosa, alcoholic ingestion and seizure disorders (3,4,5). The characteristic radiographic images show parallel rows of short metallic radiodensities due to metal plates that hold the bristle in place (4). Urgent endoscopic removal is advisable (5). Rarely laparotomy may be needed because of its irregular shape and horizontal position between the gastric body and the outlet (3,6).

References

1. Tonkic A, Bogdanovic Z, Grandic L. Successful endoscopic removal of a swallowed toothbrush: case report. *Case Rep Gastroenterol* 2011;5(1):122-4
2. Lu XL, Cao HL, Qian KD. Endoscopic removal of an accidentally swallowed toothbrush. *Intern Med.* 2008; 47(20):1797-8
3. Lal D. Inadvertent swallowing of toothbrush. *N Z Med J* 2010;123(1321):69-70
4. Mughal M. Accidental ingestion of a toothbrush. *Arch Emerg Med* 1986;3:119-23
5. Faust J, Schreiner O. A swallowed toothbrush. *Lancet* 2001;357:1012
6. Wilcox DT, Karamanoukian HL, Glick PL. Toothbrush ingestion by bulimics may require laparotomy. *J Pediatr Surg* 1994;29:1596

From the PG Dept. of Medicine Acharya Shree Chander College of Medical Sciences & Hospital, Sidhra, Jammu, J&K, India

Correspondence to : Dr Vijant Singh Chandail; 10, Jai Niwas; Amphalla; Jammu; J&K; India. Pin- 180001